

Case 1



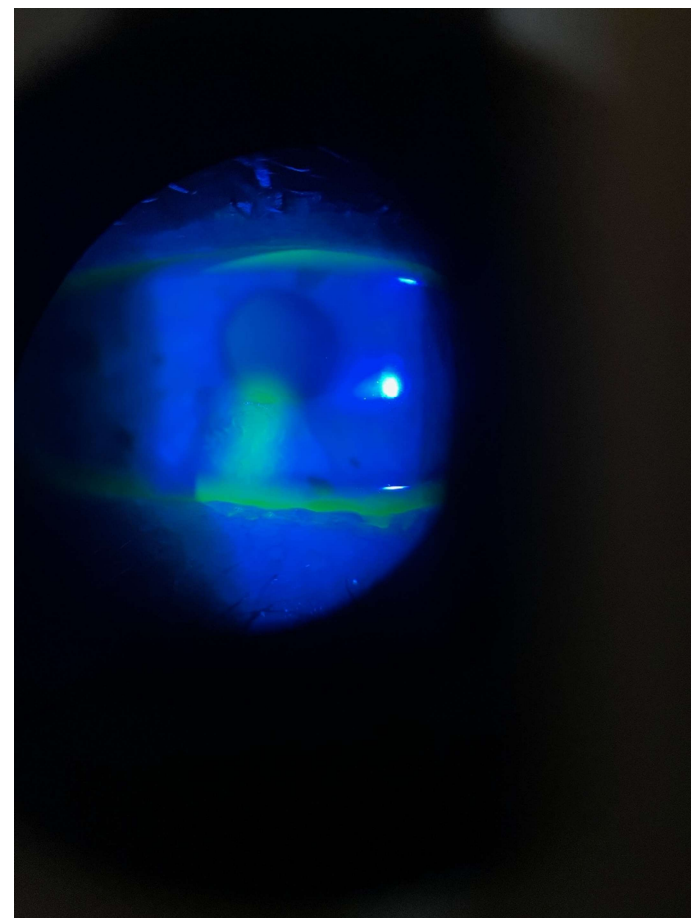
35-year-old male, presenting with intense corneal pain in LE early this morning; now pain, tearing and photophobia; Hx corneal foreign body removal (8/12 ago); no CL wear

Vision with spectacles: RE 6/5 LE 6/18

Slit lamp (local anaesthesia to aid viewing): left cornea as shown; mild/moderate diffuse conjunctival redness; loose epithelium at edges of lesion; no AC reaction but pupil constricted relative to RE

Current meds/therapies: None; not a CL wearer

Provisional Dx? Initial Mx? Follow-up and expected ongoing Mx?



Case 2



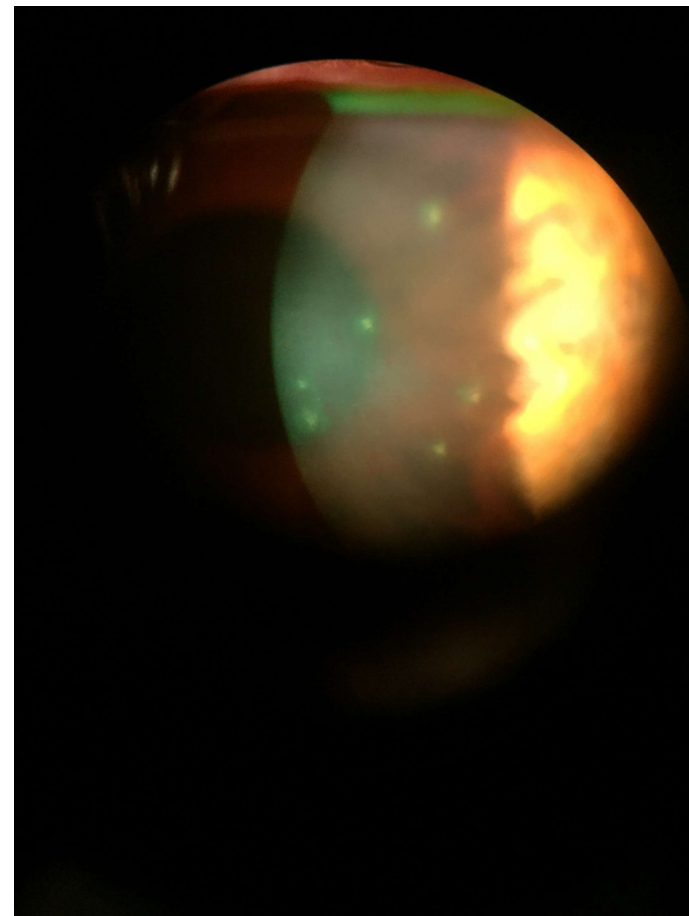
28-year-old female, second follow up visit following Dx of a bilateral follicular conjunctivitis 10 days ago; now complaining of reduced vision in RE; SiHy CL wearer but lenses left out past week or so

Vision with spectacles: RE 6/12- LE 6/4

Slit lamp: R cornea as shown (similar appearance to last visit); no significant NaFl staining; L cornea NAD; moderate diffuse conjunctival redness both eyes; follicular reaction upper and lower tarsus both eyes; ?decreased slightly from previous visit; no AC reaction; preauricular nodes still raised on both sides

Current meds/therapies: Using Systane prn in both eyes

Provisional Dx? Initial Mx? Follow-up and expected ongoing Mx?



Case 3



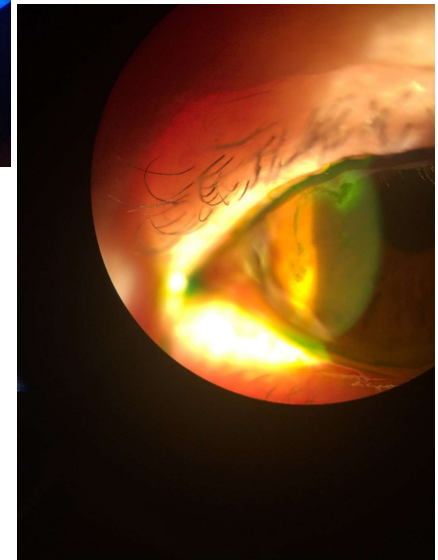
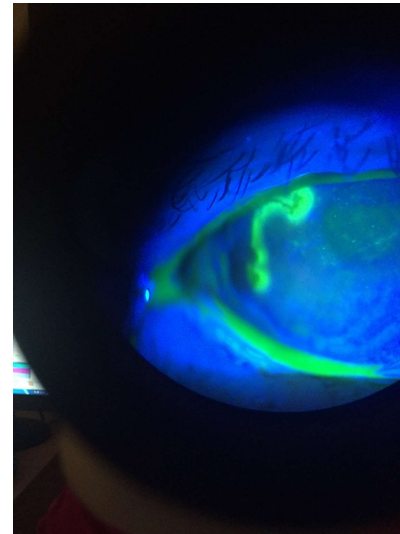
62-year-old male, complaining of mildly painful LE past day or so; Dx with COPD 3 years ago; uses inhaled corticosteroids for exacerbations; just finished a course of ICS; hasn't experienced this before

Vision with spectacles: RE 6/6 LE 6/18+

Slit lamp: L cornea as shown with NaFl and lissamine green; R cornea NAD; moderate diffuse conjunctival redness LE; scattered follicle upper tarsus; 1+ cells AC; L preauricular node slightly tender; IOPs R 16 and L 15 mmHg

Current meds/therapies: Salmeterol inhaler; Budesonide inhaler; BP meds

Provisional Dx? Initial Mx? Follow-up and expected ongoing Mx?



Case 4



45-year-old male, complaining of uncomfortable right eye past 2 days; watering quite a bit; no significant associations other than recovering from what he thinks was a bad cold; has 'had conjunctivitis in the past'

Vision with spectacles: RE 6/5 LE 6/5

Slit lamp: RE temporal conj. and lid as shown; couple of small vesicles upper lid RE; corneas NAD both eyes with no NaFl staining; odd follicle upper and lower tarsus RE; LE NAD; No AC reactions; Nodes unremarkable

Current meds/therapies: Nil

Provisional Dx? Initial Mx? Follow-up and expected ongoing Mx?

